


. * . ** . ***



≡ Abstract ≡

A Case of Progressive Proliferative Retinopathy in Incontinentia Pigmenti after Photocoagulation

Kyuchul Rhee, M.D., Young-Sik Kim, M.D.*,
Il Whan Kim, M.D.** , Khul Huh, M.D.***

A 11-days-old female was diagnosed as incontinentia pigmenti by skin biopsy was referred for ophthalmological examination. The fundus of the right eye showed vacularization only in the posteroir pole and neovasculariza-tion in the junctional area between vascular and avascula retina. Systemic

< : 1999 10 5 , : 1999 12 13 >

Address reprint requests to Kyuchul Rhee, M.D.
Department of Ophthalmolgy, College of Medicine, Korea University, Ansan Hospital
#516 Kojan-dong, Ansan-city, Kyungki-do, 425-020, Korea
Tel : 82-345-412-5160 ~ 1, Fax : 82-345-414-8930

*
Department of Pathology, College of Medicine, Korea University, Ansan Hospital, Ansan, Korea*

**
Department of Dermatology, College of Medicine, Korea University, Ansan Hospital, Ansan, Korea**

Department of Ophthalmology, College of Medicine, Korea University, Kuro Hospital, Seoul, Korea***

evaluation revealed no associated abnormality. At 22 days of age, we ablated avascular retina with indirect diode laser photocoagulation under general anesthesia. Despite extensive 360 degree photocoagulation, fibrovascular proliferation was found to extend into vitreous cavity from optic disc 3 weeks after photocoagulation(J Korean Ophthalmol Soc 41:272~275, 2000).

Key Words : Incontinentia pigmenti, Fibrovascular proliferation, Photocoagulation

(incontinentia pigmenti)

X

1).

(phthisis)

1/3

(Fig. 2a).

22

2).

가

가

360

1981

3)

(power 500mW, duration 0.1msec, (Fig. 2b).

4)

3354)

18.01mm,

17.98

1991

mm

10mm,

11

10.5mm

(Tonopen)

9,

8mmHg

3

+3.0-

가

2.0 Axis180

, +3.25-1.5Axis110

360

3

가

(Fig. 2c).

28

39

가

가

(eosinophil)

(incontinentia pigmentosa)

X

가

11

(Fig. 1a, b).

5).

X

Xp11 band

mapping

가

2).

90%

2).

. 1976 Carney

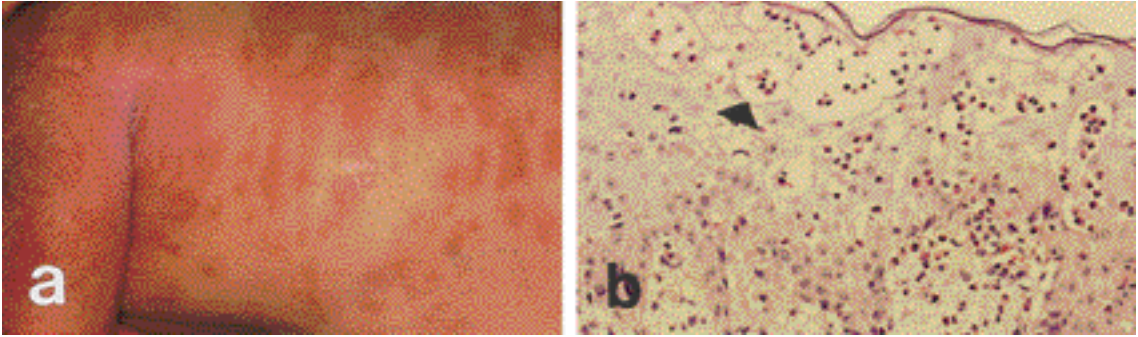


Figure 1-a. Patches and vesicles on the trunk and extremities in 11 day old female. b. Light microscopic finding showing characteristic intraepithelial vesicles containing numerous eosinophils(arrow head)(H-E stain, x200).

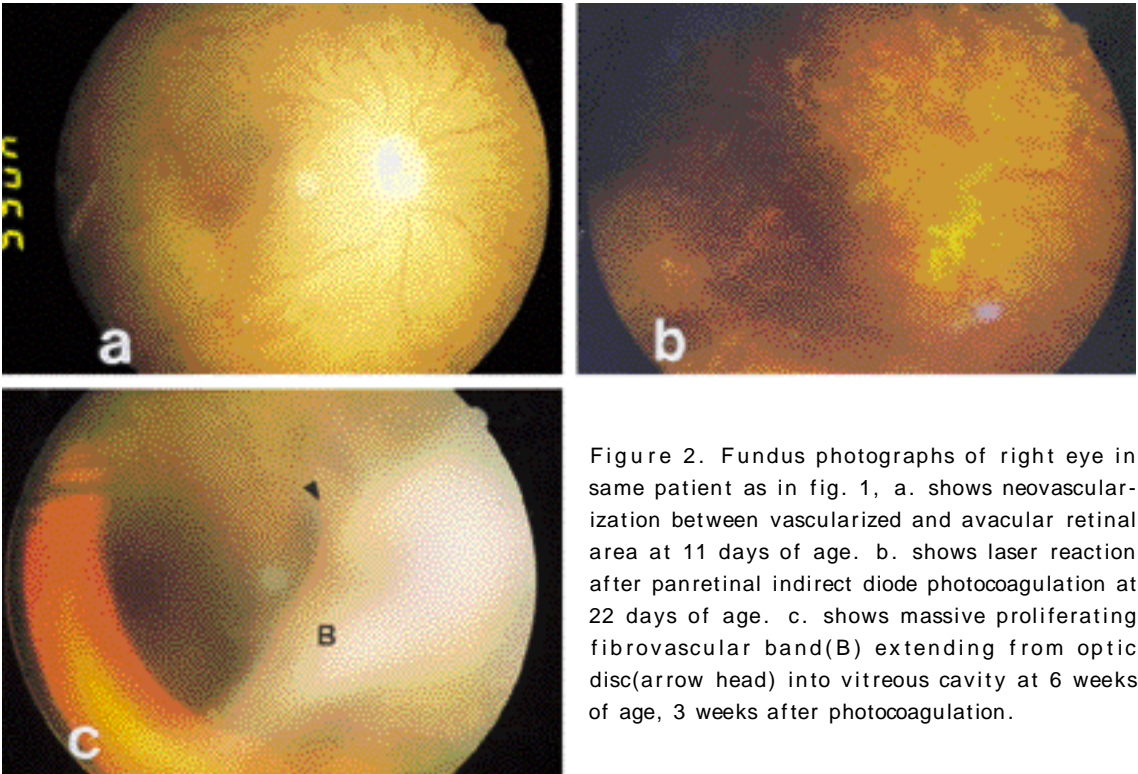



Figure 2. Fundus photographs of right eye in same patient as in fig. 1, a. shows neovascularization between vascularized and avascular retinal area at 11 days of age. b. shows laser reaction after panretinal indirect diode photocoagulation at 22 days of age. c. shows massive proliferating fibrovascular band(B) extending from optic disc(arrow head) into vitreous cavity at 6 weeks of age, 3 weeks after photocoagulation.



REFERENCES

8) 가 11

가

1) 가 11

가

4,9) 가

4,10) 가

가

가

Shah

가

4) 가

11

가

3

가

1) Goldberg MF, Custis PH : Retinal and other manifestations of incontinentia pigmenti(Bloch-Sulzberger syndrome). *Ophthalmology*, 100(11): 1645-1654, 1993.

2) Carney RGJ : Incontinentia pigmenti - a world statistical analysis. *Arch Dermatol*, 112:535-542, 1976.

3) : Incontinentia pigmenti 1 , 22:463-467, 1981.

4) Yu YS, Cho BJ : Cryotherapy for retinopathy of incontinentia pigmenti. *Korean J Ophthalmol*, 5(1):47-50, 1991.

5) Lenz W : Zur Genetik der Incontinentia pigmenti. *Ann Paediatr*, 1996:149-165, 1961.

6) Ferreira RC, Ferreira LC, Forstot L, King R : Corneal abnormalities associated with incontinentia pigmenti. *Am J Ophthalmol*, 123(4):549-551, 1997.

7) Manthey R, Apple DJ, Kivlin JD : Iris hypoplasia in incontinentia pigmenti. *J Pediatr Ophthalmol Strabismus*, 19:279-280, 1982.

8) Raab EL : Ocular lesions in incontinentia pigmenti. *J Pediatr Ophthalmol Strabismus*, 20(2): 42-48, 1983.

9) Wald KJ, Mehta MC, Katsumi O, Sabates NR, Hirose T : Retinal detachments in incontinentia pigmenti. *Arch Ophthalmol*, 111(5):614-617, 1993.

10) Nix RR, Apple KJ : Proliferative retinopathy associated with incontinentia pigmenti. *Retina*, 1:156-161, 1981.

11) Watzke RC, Stevens TS, Carney RGJ : Retinal vascular changes of incontinentia pigmenti. *Arch Ophthalmol*, 94:743-746, 1076.

12) Nishimura M, Oka Y, Takagi I : The clinical feature and treatment of the retinopathy of Bloch-Sulzberger syndrome(incontinentia pigmenti). *Jpn J Ophthalmol*, 24:310-319, 1980.

13) Beat W, Rentsch F : Uber das pseudogium bei der incontinentia pigmenti. *Klin Monatsbl augenheilkd*, 165:19-23, 1974.

14) Shah GK, Summers CG, Walsh AW, Neely KA : Optic nerve neovascularization in incontinentia pigmenti. *Am J Ophthalmol*, 124:410-412, 1997.